



# Patterns and prevalence of sinonasal inverted papilloma in Port Harcourt metropolis, Nigeria: Computed tomography findings

Michael Promise Ogolodom<sup>1</sup>, Okechukwu Felix Erondur<sup>2</sup>, Anthony Chukwuka Ugwu<sup>3</sup>, Christopher Chukwuemeka Ohagwu<sup>3</sup>

<sup>1</sup>Department of Radiology, Braithwaite Memorial Specialist Hospital, Port Harcourt, Rivers State, Nigeria, <sup>2</sup>Imaging Department of Image Diagnostics LTD Port Harcourt, Rivers State, <sup>3</sup>Department of Radiography and Radiological Sciences, Faculty of Health Sciences and Technology, Nnamdi Azikiwe University Anambra State, Anambra State, Nigeria

## Keywords:

Computed tomography, inverted papilloma, sinonasal spaces

## Correspondence:

Ogolodom, Michael Promise, Department of Radiology, Braithwaite Memorial Specialist Hospital, Port Harcourt, Rivers State, Nigeria.  
Email: mpos2007@yahoo.com.  
Phone: +23-4803997393

Received: 26 September 18;

Accepted: 28 October 18

doi: 10.15713/ins.idmjar.94

## Abstract

**Background:** Inverted papilloma is a rare and slow-growing benign epithelial neoplasm that has a high tendency of changing into malignant tumor which usually occurs in the sinonasal cavities. This pathology was first described and characterized by Ward and Ringertz, respectively. Inverted papilloma has high capability of invading nearby structures usually from the lateral wall of nasal cavity and often extends into the adjacent maxillary or ethmoidal sinuses.

**Aim:** This study is aimed to evaluate the patterns and prevalence of sinonasal inverted papilloma diagnosed on computed tomography (CT) in Port Harcourt, and the following specific objective was also evaluated: Age and sex distributions of the pathology.

**Materials and Methods:** The craniofacial CT examinations were performed using general electric machines with standard scanning protocols and parameters. A retrospective cross-sectional research design was adopted for this study, and all CT radiological reports of patients who underwent craniofacial CT scan from January 2012 to May 2017 and met the inclusion criteria were selected using data capture sheet. Approval for this study was obtained from the management of the study centers. The obtained data were analyzed using descriptive statistics on SPSS version 20.

**Results:** Of 1572 data evaluated, 6.5% ( $n = 102$ ) had sinonasal inverted papilloma. Nasal obstruction was the most common symptom, 36.91% ( $n = 55$ ), and the least was frontal headache, 6.71% ( $n = 10$ ). Paranasal Sinuses (PNSs) were highly affected, 44.29% ( $n = 62$ ). 66.7% ( $n = 68$ ) were male and 33.3% ( $n = 34$ ) were female. The age group of 31–45 years was highest, 41.18% ( $n = 42$ ), and 0–15 years was least, 2.94% ( $n = 3$ ).

**Conclusion:** The prevalence of sinonasal inverted papilloma was low in this study. PNSs were highly affected than nasal cavities. Sinonasal inverted papilloma was common in males than females, and young adults were commonly affected by the pathology.

**Clinical Significance:** Adequate knowledge of the patterns and prevalence of sinonasal inverted papilloma diagnosed on CT in Port Harcourt would be useful information to the ear, nose, and throat surgeons in planning their functional endoscopy sinus surgery and also in managing patients who cannot afford to pay for PNS CT investigations in this locality.

## Introduction

Inverted papilloma is a rare and slow-growing benign epithelial neoplasm that has a high tendency of metamorphosing into malignant tumor which usually occurs in the sinonasal cavities.<sup>[1-3]</sup>

This pathology was first described and characterized by Ward and Ringertz, respectively.<sup>[2,4]</sup> Inverted papilloma has a high capability of invading nearby structures usually from the lateral wall of nasal cavity and often extend into the adjacent maxillary or ethmoidal sinuses.<sup>[2,5-12]</sup> Nasal papillomas are rare representing

only 0.4–4.7% of all sinonasal tumors.<sup>[1,5,13]</sup> There are different pathologic descriptions of sinonasal papilloma which includes fungiform papilloma, inverted papilloma, epithelioma, transitional cell papilloma, Schneideran papilloma, and cylindrical cell papilloma.<sup>[5,7,14,15]</sup> This pathology usually affects patients from 40 to 70 years old and more prevalent among the male population when compared to the female population.<sup>[1,5,7]</sup> The common symptoms of sinonasal inverted papilloma include nasal obstruction, facial pain, anosmia, inflammation, epistaxis, rhinorrhea, and frontal headache. The etiology is unknown though may be ascribed to the environmental pollutions and the lifestyle of individuals.<sup>[16-18]</sup> The pathology literature by Barnes *et al.*<sup>[6]</sup> reviewed an idiosyncratic whole mucosal morphology of sinonasal inverted papilloma called a convoluted cerebriform pattern. According to Ojiri *et al.*<sup>[11]</sup> and Barnes *et al.*,<sup>[6]</sup> an inverted papilloma presents as a polypoid growth enveloped by a convoluted cerebriform mucosal.

Magnetic resonance imaging (MRI) and computed tomography (CT) are the modalities of choice for the diagnosis of sinonasal inverted papilloma. The former modality can be used to define the extent of inverted papilloma and possibly to determine the associated malignancy.<sup>[1,19,20]</sup> CT scan of the nasal and paranasal sinuses (PNS) has replaced conventional X-ray, especially before functional endoscopic sinus surgery (FESS), due to anatomical details needed by the ear, nose, and throat (ENT) surgeons.<sup>[13,21]</sup> CT has also found superiority to MRI in carrying out FESS, also allows for the evaluation of the patency among the intercommunicating pathways of the sinonasal cavities, the regional anatomy, extent of the pathology, and bony erosion, and provides the ENT surgeons the opportunity to clearly visualize the impact of an obstruction and anatomical variations in the pathway.<sup>[22-24]</sup> Inverted papilloma on computed tomogram shows mass in the nasal cavity with opacification of the sinuses and bony erosion.<sup>[25]</sup> Calcifications of this pathology are usually linear in shape but sometimes clump-like.<sup>[26,27]</sup>

Industrial activities which contribute greatly to environmental pollution are common in Port Harcourt metropolis, the administrative capital of Rivers State. Research shows that high prevalence of sinonasal pathologies including inverted papilloma are associated with environmental pollution.<sup>[17,18,24,28]</sup> Adequate knowledge of the patterns and prevalence of sinonasal inverted papilloma diagnosed on CT in Port Harcourt metropolis would be useful information to the ENT surgeons in planning their FESS in this locality. To the best of our knowledge, our study is the first both locally and internationally to capture data on the patterns and prevalence of sinonasal inverted papilloma in Port Harcourt Metropolis, Nigeria. The following specific objectives were evaluated in this study.

1. Patterns and prevalence of sinonasal inverted papilloma in our locality
2. Age and sex distributions of the pathology.

**Materials and Methods**

All patients underwent craniofacial CT on multislice general electric (GE) machines. Standard scanning protocols and

parameters for craniofacial CT were used in performing the CT scan by qualified radiographers. Images acquired were interpreted by consultant radiologists working in the selected study centers. This is a retrospective cross-sectional research design which involved randomly reviewed of all the CT radiological reports of patients who underwent craniofacial CT scan between January 2012 and May 2017 due to different complaints. Inclusion criteria involve reports with information such as age, sex, clinical complaints, and patterns of radiological findings. According to these criteria, a total of 1572 patients’ radiological reports met the inclusion criteria to form the study population. Approval and permission to collate data for this study were obtained from the management of the respective study centers. All patients’ information retrieved from the radiological reports was handled with a high level of confidentiality and was used for the purpose of this research only. A structured data captured sheet was used for data collection. The data were presented as numbers and percentages for nominal data in means and standard deviation for numerical values. Statistical analysis was performed using SPSS version 20.0 for Mac (SPSS Inc., Chicago, IL, USA).

**Results**

We examined 2457 patients’ reports, and 1572 of these with a mean age of 35.11 ± 12.58 years (4–85 years) were included in this study. Of 1572 radiological reports evaluated retrospectively, only 6.5% (*n* = 102) had inverted papilloma [Table 1]. The result also shows that obstructive nasal cases were the most common presenting symptoms of inverted papilloma which is 36.91% (*n* = 55), followed by rhinorrhea, 20.13% (*n* = 30), and the least was frontal headache, 6.71% (*n* = 10) [Table 2]. Of 102 patients who had inverted papilloma in this study, 140 patterns of involvement were identified. In most cases, about 80% (*n* = 82) of patients presented with multiple areas of involvement of

**Table 1:** Frequency and percentage distribution of sinonasal inverted papilloma

Sinonasal inverted papilloma	Frequency ( <i>n</i> , %)
Presence	102 (6.5)
Absence	1470 (93.5)
Total	1572 (100)

**Table 2:** The presented clinical indications of sinonasal inverted papillomas studied

Symptoms	Frequency and percentage ( <i>n</i> , %)
Epistaxis	25 (16.78)
Anosmia	14 (9.40)
Facial pains	15 (10.07)
Nasal obstruction	55 (36.91)
Frontal headache	10 (6.71)
Rhinorrhea	30 (20.13)
Total	149 (100)

**Table 3:** Sinuses involvement of inverted papillomas

Patterns/involvement of inverted papilloma	Frequency and percentage (n, %)
Paranasal sinuses	62 (44.29)
Maxillary sinuses	24 (17.14)
Frontal sinuses	12 (8.57)
Sphenoid sinuses	8 (5.71)
Ethmoid sinuses	18 (12.87)
Nasal cavities	46 (32.89)
One sided	29 (20.71)
Bilateral	17 (12.18)
Sinonasal	32 (22.82)
Total	140 (100)

**Table 4:** Sex distribution of inverted papilloma studied

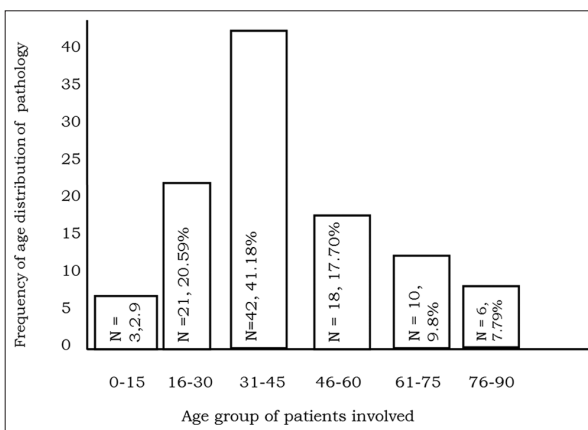
Sex	Frequency/percentage (n, %)
Male	(n=68, 66.7)
Female	(n=34, 33.3)
Total	102 (100)

the pathology. Those that involved the PNS only were highest 44.29% (n = 62) followed by nasal cavities only, 32.29% (n = 46), and the least involved both sinuses and nasal cavities. Of 62 cases who involved PNS, 17.14% (n = 24) was maxillary sinuses as highest and the least was sphenoid sinuses 5.7% (n = 8). One-sided nasal cavity was highly involved 20.71% (n = 29) out of 32.89% (n =46) cases of nasal cavities involvement [Table 3]. Of 102 patients who had inverted papilloma in this study, the male-to-female ratio was 1:1.9 which is 66.7% (n =68) males and 33.3% (n =34) females [Table 4]. Figure 1 shows the age group distribution of inverted papilloma. Age group 31-45 years had the highest cases 41.18% (n=42) followed by 16-30 years 20.59% (n=21) and the least was age group 0-15 years (n=3).

**Discussion**

Inverted papilloma of the sinonasal cavities normally starts from the lateral wall of the nasal cavities and extends into the PNS. In our study, the prevalence of sinonasal inverted papilloma was quite low as <10% have the pathology, which accords with the findings in other related studies conducted by Som and Brandwein<sup>[5]</sup> and Yousem.<sup>[13]</sup> According to them, nasal papilloma accounts for about 0.4–4.7% of sinonasal tumors. The most prevalent findings with regard to the presenting symptoms of inverted papilloma in our study were nasal obstructions and the least was frontal headache. This was in agreement with study and some literatures by Thorp *et al.*, Chai *et al.*, and Busquets and Hwang.<sup>[14,28,29]</sup>

PNS were highly involved when compared to the nasal cavities in this study. The commonly affected sinuses by this pathology were maxillary sinuses. This could be attributed to the anatomical location of this sinus which is inferior to the



**Figure 1:** Age distribution of the sinonasal inverted papillomas

nasal cavities. This finding is in accordance with the statement of Som and Brandwein<sup>[5]</sup> and Yousem.<sup>[13]</sup> According to them, nasal papillomas are rare and account for only 0.4–4.7% of all sinonasal cavities inverted papilloma. In this study, nasal cavity involvement of inverted papilloma was 32.89% and this discrepancy in our results could be attributed to the sample sizes used and the geographical variations. Young adults are significantly more affected by this pathology. This is in keeping with the findings of related studies conducted by Ologe and Adeniji, Ogolodom *et al.*, and Verma *et al.*<sup>[16,23,24]</sup> In their studies, majority of those affected this pathology were within the 1<sup>st</sup> and 3<sup>rd</sup> decades. This has been attributed to the fact that younger adults are more exposed to environmental factors such as dusty and polluted environments as a result of their search for white collars job, irregular checkup, and treatment.<sup>[16]</sup> The frequency of sinonasal inverted papilloma in male was more than female in this study. This is in concordant with previous studies conducted by Ojiri *et al.*,<sup>[1]</sup> Katori and Tsukuada,<sup>[3]</sup> Som and Brandwein,<sup>[5]</sup> and Michaels and Thorp *et al.*<sup>[7,14]</sup> Male preponderance was noted in this study, which could be attributed to the fact that males were usually highly exposed to the predisposing factors of inverted papilloma when compared to their female counterpart due to the nature of their jobs.<sup>[17]</sup>

**Conclusion**

The prevalence of sinonasal inverted papilloma in our study is quite low and very rare among those that underwent craniofacial CT included in this study. Nasal obstruction was the most prevalent clinical complaint. The greater number of the inverted papilloma cases involved the PNS. Young adults were commonly affected by inverted papilloma in this study. The frequency of sinonasal inverted papilloma was highest in males than females.

**Conflicts of Interest**

The authors declared that they have no conflicts of interest.

## Acknowledgment

The authors wish to thank the management of Image Diagnostics, Union Diagnostics and Crystal Diagnostics Centers for allowing us to collate data in their facilities.

## References

- Ojiri H, Ujita M, Tada S, Fukuda K. Potentially distinctive features of sinonasal inverted papilloma on MR imaging. *Am J Radiol* 2000;175:165-8.
- Ringertz N. Pathology of malignant tumors arising in the nasal and paranasal cavities and maxilla. *Acta Otolaryngol* 1938;27:31-42.
- Katori H, Tsukuda M. Staging of surgical approach of sinonasal inverted papilloma. *AurisNasus Larynx* 2005;32:257-63.
- Ward N. A mirror of the practice of medicine and surgery in the hospitals of London. *Lond Hosp Lancet* 1854;2:87-98.
- Som PM, Brandwein MS. Tumors and tumorlike conditions: Sinonasal cavities-inflammatory diseases, tumors, fractures and postoperative finding. In: Som PM, Curtin HD, editors. *Head and Neck Imaging*. 4<sup>th</sup> ed. St Louis: Mosby; 1996.
- Barnes L, Verbin RS, Gnepp DR. Diseases of the nose, paranasal sinuses and nasopharynx. In: Barnes L, editor. *Surgical Pathology of the Head and Neck*. Vol.1. New York: Marcel Dekker; 1985. p. 403-51.
- Michaels L. Benign mucosal tumors of the nose and paranasal sinuses. *Semin Diagn Pathol* 1996;13:113-7.
- DeSanto LW. Neoplasms. In: Cummings CW, Fredrickson JM, Harker LA, Krause CJ, Schuller DE, editors. *Otolaryngology-Head and Neck Surgery*. 2<sup>nd</sup> ed. St Louis: Mosby-Year Book; 1993. p. 754-64.
- Chow JM, Ching VH. Epithelial tumors of paranasal sinuses and nasal cavity. *J Radiol N Am* 1993;31:61-73.
- Maffe MF. Non-epithelial tumors of the paranasal sinuses and nasal cavity. *Radiol Clin N Am* 1993;31:75.
- Mishra D, Rajeeu S, Saxena R. A study of the clinical profile and management of inverted papilloma. *Int J Otorhinolaryngol* 2009;10:1-4.
- Eggers G, Muhling J, Hassfield S. Inverted papilloma of paranasal sinuses. *J Cranio-Maxillofac Surg* 2007;35:21-5.
- Yousem DM. Imaging of sinonasal inflammation disease. *Radiol* 1993;188:1303-14.
- Thorp MA, Oyarzabal-Amigo MF, du Plessis JH, Sellars SL. Inverted papilloma: A review of 53 cases. *Laryngoscope* 2001;111:1401-5.
- Vrabee DP. The inverted schneiderian papilloma. A 25 years study. *Laryngoscope* 1994;104:582-605.
- Ologe FE, Adeniji KA. Clinico-pathological study of nasal masses in Illorin, Nigeria. *Nig J Surg* 2003;9:14-6.
- Nwachukwu AN, Chukwuoch EO, Igbudu O. A Survey of the effects of air pollution on diseases of the people of rivers state Nigeria. *Afr J Environ Sci Techn* 2012;6:372-9.
- Ahmad ZA, Abdullah M. Frontal mucocele: A case report. *Annal* 2013;2:294-7.
- Lee TJ, Li SP, Fu CH, Hung CC, Chama PH, Chen YW. Extensive paranasal sinus mucocele: a 15 years review of 82 cases. *Am J Otorhinolaryngol Head Neck Med Surg* 2009;30:234-8.
- Sharm BN, Panta OB, Lohan B, Khanal U. Computed tomography in the evaluation of pathological lesions of paranasal sinuses. *J Nepal Health Res Couc* 2015;13:117.
- Pasquini E, Sciarretta V, Farneti G, Modugno GC, Ceroni AR. Inverted papilloma: Report of 89 cases. *Am J Otolaryngol* 2004;25:178-85.
- Schurneicht HF, Lindsay JR. Benign cysts of the paranasal sinuses. *Arch Otolaryngol* 1949;49:609-30.
- Ogolodom MP, Erundu OF, Egbeyemi OO. Patterns and prevalence of mucocoeles among patients referred for cranio-facial computed tomography in Port Harcourt metropolis. *Int J Adv Res Rev* 2018;3:70-8.
- Verma J, Tyagi S, Srivastava M, Agarwal A. Computed tomography of paranasal sinuses for early diagnosis of nasal and sinus pathology. *Int J Otorhinolaryngol Head Neck Surg* 2016;2:70-1.
- Arotiba GT. Malignant neoplasma of the maxillary antrum in Nigerians. *West Afr J Med* 1998;17:173-8.
- Milonski J, Pietkiewicz P, Urbaniak J, Olszewski J. Incidence and nature of unilateral pathological lesions of paranasal sinuses removed by endoscopic surgery. *Otolaryngol Polska* 2014;68:83-8.
- Cure JK, Schabel S. Sinuses. In: Sulton, D, editor. *Concise Textbook of Clinical Imaging*. 1<sup>st</sup> ed. Philadelphia, PA, USA: Mosby-Year book; 1995. p. 857-71.
- Chai CK, Tang IP, Prepageran N. A review of inverted papilloma at a tertiary centre: A six- year experience. *Int J Otolaryngol Head Neck* 2013;2:156-8.
- Busquets JM, Hwang PH. Endoscopic resection of sinonasal inverted papilloma: A meta-analysis. *Otolaryngol Head Neck Surg* 2006;135:476-82.

**How to cite this article:** Ogolodom MP, Erundu OF, Ugwu AC, Ohagwu CC., Patterns and prevalence of sinonasal inverted papilloma in Port Harcourt metropolis, Nigeria: Computed tomography findings. *Int Dent Med J Adv Res* 2018;4:1-4.

This work is licensed under a Creative Commons Attribution 4.0 International License. The images or other third party material in this article are included in the article's Creative Commons license, unless indicated otherwise in the credit line; if the material is not included under the Creative Commons license, users will need to obtain permission from the license holder to reproduce the material. To view a copy of this license, visit <http://creativecommons.org/licenses/by/4.0/> © Ogolodom MP, Erundu OF, Ugwu AC, Ohagwu CC. 2018